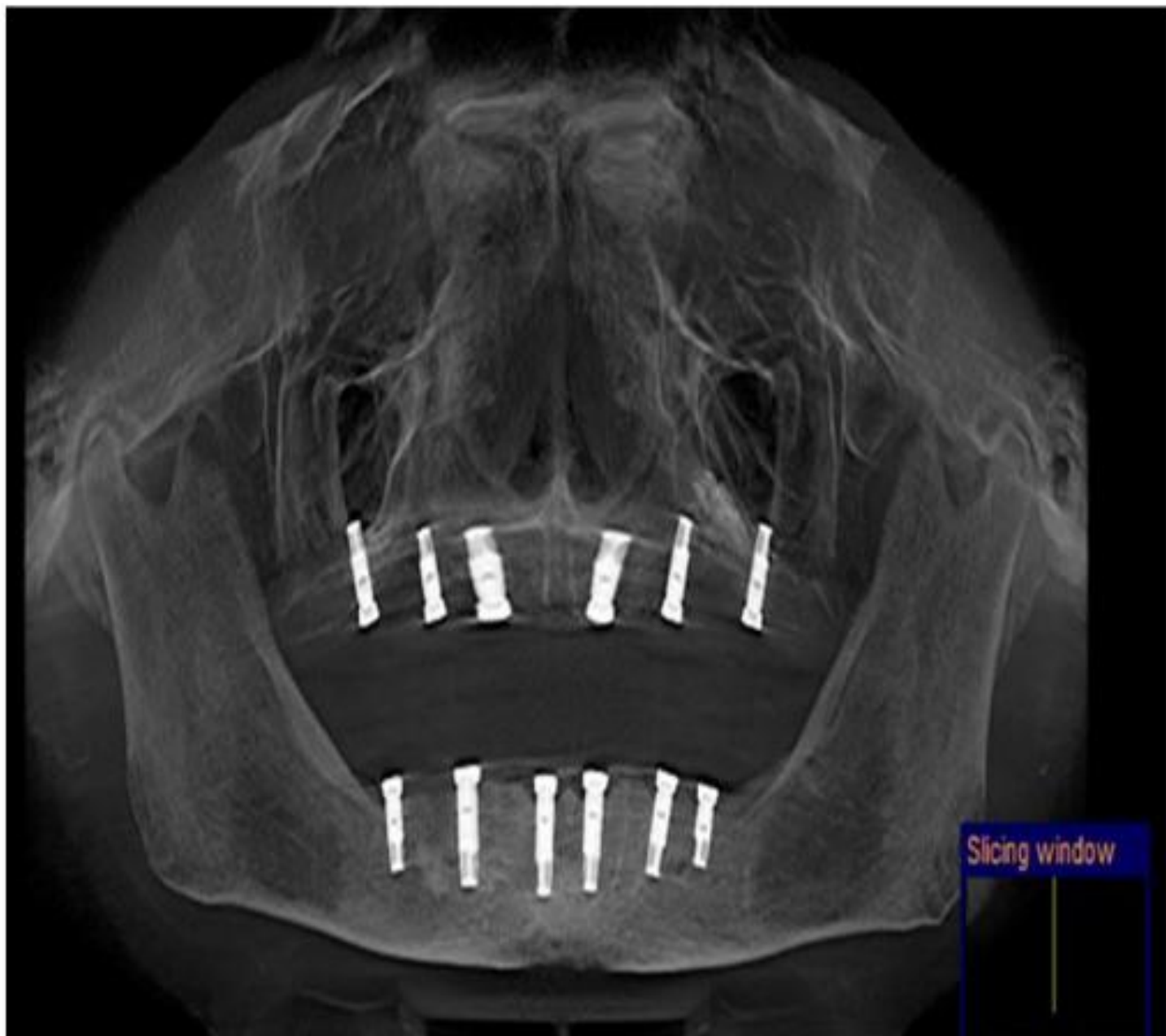

Case #2 with Theragem

- 61 yr. old woman with history of dental implants. Shortly after completing this procedure, she noticed changes in her right breast that kept getting worse. After 18 months and consulting with specialists, she had her dental implants removed by a biological dentist. She consulted with several health practitioners, and had a thermogram. Bloodwork shows evidence of infection, folic acid deficiency, one cancer marker negative.
- We began Theragem treatments. Initially we did Elation w/ sapphire; spleen w/diamond and carnelian; emerald on the right breast. This continued for 6 treatments and then diamond and carnelian was added after the emerald on the breast.
- After 4 more treatments the pain was reduced considerably so we added ruby plus diamond/carnelian on the right breast in addition to the spleen therapy. She has had a total of 20 treatments to date.
- We had her repeat the thermogram last week. **Comparisons show less extensive lymphatic involvement (approx. 50% less)** with the focus becoming more concentrated in one area. The skin lesion itself has gone from dark scabs to very red areas without scabs. The skin area now is becoming less red and the areas are becoming flatter.
- We've recommended getting another opinion and running other blood tests more specific for breast cancer.



Dental Relationship Chart

Joints	Right Shoulder- elbow-hand (dental), foot, hip, knee	Right: Thd, anterior hip/knee medial ankle	Right: Shoulder-elbow-hand (medial), foot, hip, knee	Right: Forearm bone, hip, lateral ankle	Right: Forearm bone, hip, medial ankle	Left: Forearm bone, hip, medial ankle	Left: Forearm bone, hip, lateral ankle	Left: Shd (medial), h				
Mammary Glands		R I G H T C H E E K										
Endocrine Glands	Anterior pituitary	Parathyroid	Thyroid	Thyroid	Posterior pituitary	testosterone side of prostate	Proxal	Proxal	testosterone side of prostate	Posterior pituitary		
Organs	Right heart, right fallopian tube, ascending colon	Proximal, right side of stomach, esophagus	Right lung, right adrenaline	side of large	Right side of liver, gall bladder, right side of biliary duct	Right kidney bladder, ureter, prostate, testis, ovary	Left kidney, bladder, ureter, prostate, testis, ovary	Left side of liver; biliary ducts	Left lung adrenaline			
Teeth Pictured												
Names of Teeth	Right upper 2nd molar (molar)	Right upper 2nd molar	Right upper 1st molar	Right upper 2nd bicuspid (pre-molar)	Right upper 1st bicuspid (pre-molar)	Right upper canine (cuspid)	Right upper lateral incisor	Right upper central incisor	Left upper central incisor	Left upper lateral incisor	Left upper canine (cuspid)	Left upp bicuspid (pre-mo
American Nomenclature	1	2	3	4	5	6	7	8	9	10	11	12
	11	10	9	8	7	6	5	4	3	2	1	12
Names of Teeth	Right lower 2nd molar (molar)	Right lower 2nd molar	Right lower 1st molar	Right lower 2nd bicuspid (pre-molar)	Right lower 1st bicuspid (pre-molar)	Right lower canine (cuspid)	Right lower lateral incisor	Right lower central incisor	Left lower central incisor	Left lower lateral incisor	Left lower canine (cuspid)	Left low bicuspid (pre-mo
Teeth Pictured												
Organs	Right heart, uterus (ovary, fallopian)	Proximal, right side of stomach, pylorus, esophagus	Right lung, right side of large adrenaline	Right side of liver, gall bladder, right side of biliary duct	Right kidney bladder, ureter, prostate, testis, ovary	Left kidney, bladder, ureter, prostate, testis, ovary	Left side of liver; biliary ducts	Left lung adrenaline				
Endocrine Glands			Ovaries	testes/ovary	Adrenals	Adrenals	Ovaries	testis				
Mammary glands			R I G H T C H E E K									
Joints	Right: Shoulder- elbow-hand (dental), foot, hip, knee	Right: Thd, anterior hip/knee medial ankle	Right: Shoulder-elbow-hand (medial), foot, hip, knee	Right: Forearm bone, hip, lateral ankle	Right: Forearm bone, hip, medial ankle	Left: Forearm bone, hip, medial ankle	Left: Forearm bone, hip, lateral ankle	Left: Shd (medial), h				

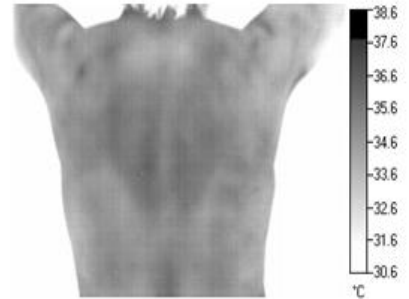
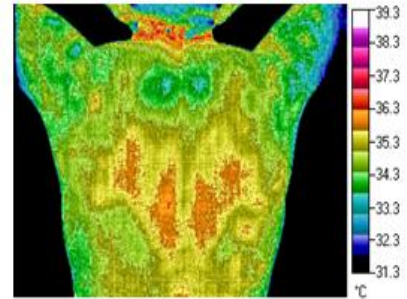
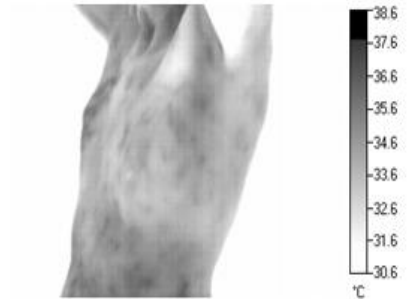
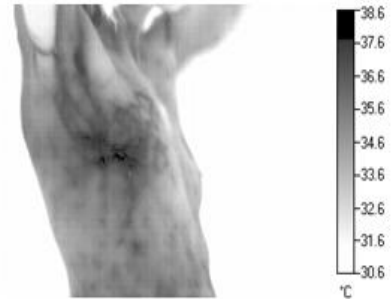
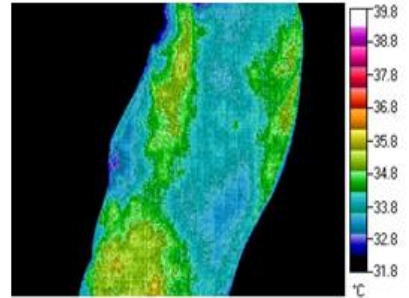
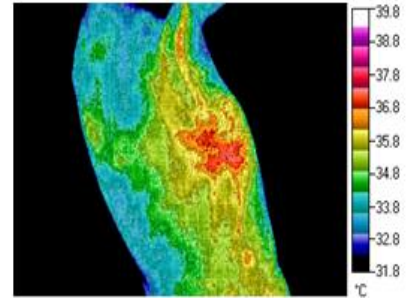

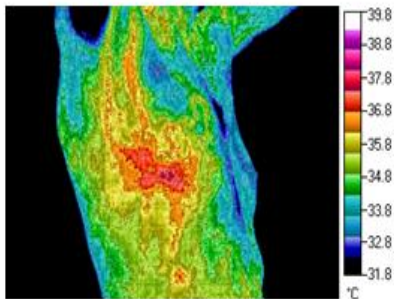
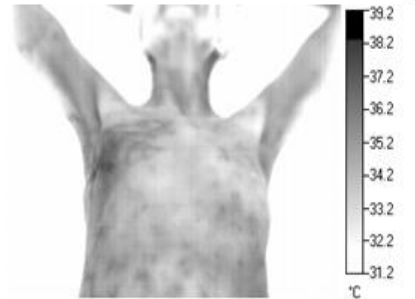
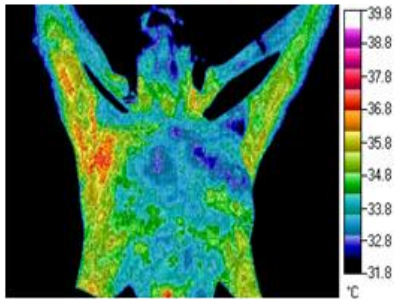
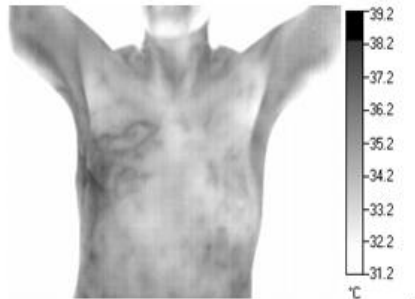
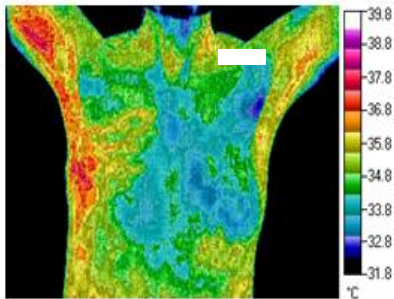
Specimen #		Control/Req Number		Pg 2		LabCorp		V 1.28	
034-253-5908-0		EC1265242							
Fasting	Micro Source	Total Urine Volume	Report Status	Clinical Information					
			S / Final						
Date Collected	Time Collected	Date Entered	Date Reported						
02/03/11	12:54	02/04/11	02/04/11						
Patient ID Number		Patient Phone Number		Patient SSN		Account			
121352						17123375			
Patient Name			Sex	Date of Birth		Direct Laboratory Services			
1			F	10/20/49		300 Mariners Plaza Suite 321			
Patient Ad					Mandeville, LA 70448				
					985-624-9186				
Comments					UPDN: 1558428227				
PATIENT AGE:			062 / -08 / -17		PHY NAME: TENPENNY, S				
Tests Requested		CMP14+LP+TP+TSH+5AC+CBC/D/Plt; Cancer Antigen (CA) 125							
TESTS	RESULT	FLAG	UNITS	REFERENCE INTERVAL	LAB				
RBC	3.68	LOW	x10E6/uL	3.80-5.10	01				
Hemoglobin	12.4		g/dL	11.5-15.0	01				
Hematocrit	36.8		%	34.0-44.0	01				
MCV	100	HIGH	fL	80-98	01				
MCH	33.7		pg	27.0-34.0	01				
MCHC	33.7		g/dL	32.0-36.0	01				
RDW	13.7		%	11.7-15.0	01				
Platelets	240		x10E3/uL	140-415	01				
Neutrophils	31	LOW	%	40-74	01				
Lymphs	52	HIGH	%	14-46	01				
Monocytes	15	HIGH	%	4-13	01				
Eos	1		%	0-7	01				
Basos	1		%	0-3	01				
Immature Cells					01				
Neutrophils (Absolute)	1.3	LOW	x10E3/uL	1.8-7.8	01				
Lymphs (Absolute)	2.2		x10E3/uL	0.7-4.5	01				
Monocytes(Absolute)	0.7		x10E3/uL	0.1-1.0	01				
Eos (Absolute)	0.0		x10E3/uL	0.0-0.4	01				
Baso (Absolute)	0.0		x10E3/uL	0.0-0.2	01				
Immature Granulocytes	0		%	0-1	01				
Immature Grans (Abs)	0.0		x10E3/uL	0.0-0.1	01				
Hematology Comments:						01			
Cancer Antigen (CA) 125		18.5	U/mL	0.0-34.0	01				
		Roche ECLIA methodology							
Lab: 01 LabCorp San Diego						Director: Kelli Hanson, MD			
13112 Evening Creek Dr So Ste 200, San Diego, CA 921284108									
For inquires, the physician may contact: Branch 800-222-7566 Lab: 205-581-3500									
LAST PAGE OF REPORT									

Thermogram #1 before Theragem

Phone: 415-928-5423 Fax: 415-928-0452

Patient Name: [REDACTED]
Type Of Exam:
Thermal Indicator:
Risk Indicator:

Date of Exam: February 16, 2011
Reported By: Cindy Crawford
Recall:
Report No: 4



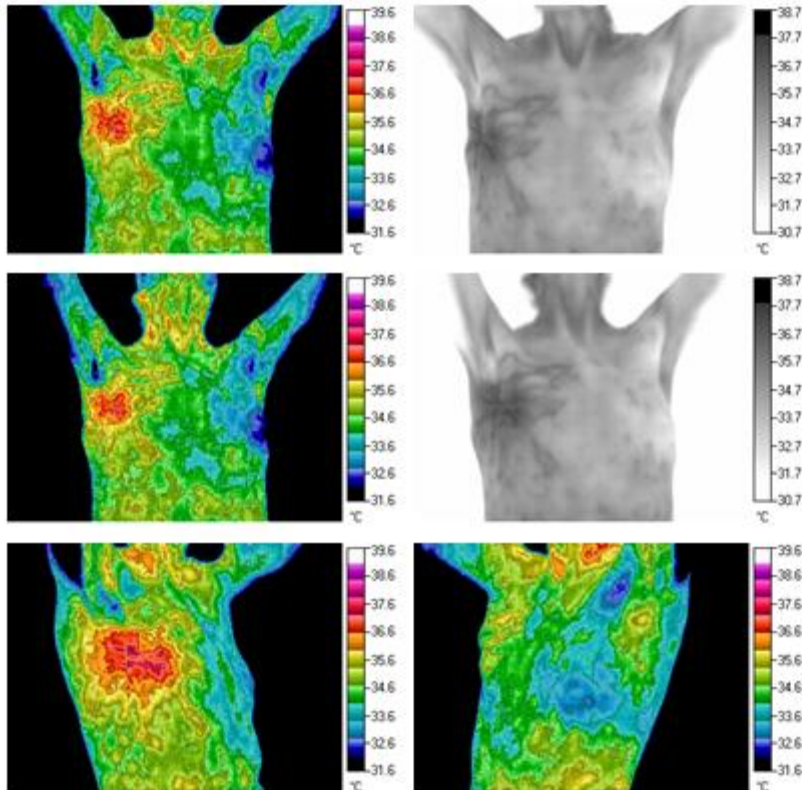
Thermogram #2 after Theragem

Core Care Imaging Center

1634 Union Street,
San Francisco, California 94123 USA
Phone: 415-928-5423 Fax: 415-928-0452

Patient Name: XXXXXXXXXX
Type Of Exam:
Thermal Indicator:
Risk Indicator:

Date of Exam: September 14, 2011
Reported By: Cindy Crawford
Recall:
Report No: 4



Patient Name: Elizabeth Bursis

